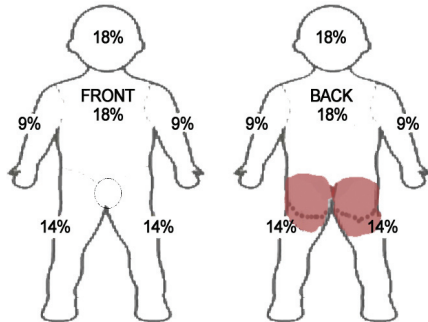


Second degree burns treated with Activon Tube[®], Actilite[®] and Eclipse[®] dressings

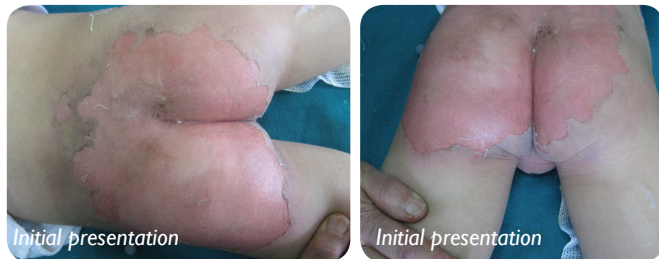
Dr. Mohammad Ali Ajam- M.D.F.R.C.S & The head of burn unit, Dr. Shervin Shalbaf- chief resident of Plastic surgery, Al-Kinidi Hospital Plastic Surgery & Burn Unit.

Background

The patient is male, 5 years old who suffered burns by hot liquid on 15th November 2009. He was hospitalised one hour after the incident.



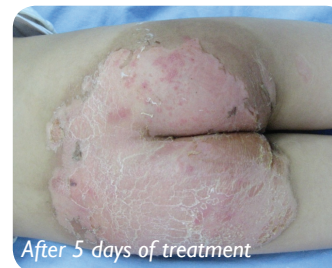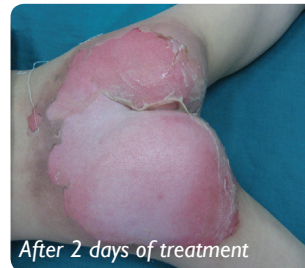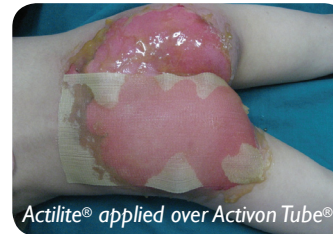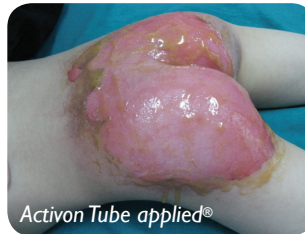The burns were to his gluteal area on both sides but his genitalia was normal. The burns were second degree, around 12% body surface.



Treatment

The treatment was started by washing the affected and surrounding gluteal area with normal saline fluid.

Activon Tube[®] was applied over the gluteal area then dressed with Actilite[®] followed by Eclipse[®].



Conclusion

With this course of treatment regime the burn was healed within a week. During dressing change the patient did not like the smell of the Actilite[®] dressing. However the pain was minimal and no need for any sedation.

