

The use of Advazorb® on a painful severe ulcer

Leanne Cook—Vascular Nurse Specialist/lecturer Practitioner, Pinderfields General Hospital, Wakefield

Introduction

A 78-year-old woman presented with a painful severe ulcer of several weeks duration to the posterior aspects of both calves. She had a history of spontaneous ulceration, and was being treated by community nurses, who arranged an urgent referral to the vascular team. Her past medical history included ischaemic heart disease, hypertension and asthma; her medications comprised amlodipine, bendroflumethiazide and aspirin, as well as various inhalers. The ulcer was causing her severe pain, for which her GP had recently prescribed co-codamol 30/500.

On examination, the patient had palpable femoral pulses but absent pulses below this level. She was unable to tolerate measurement of her ankle brachial pressures, but had abnormal monophasic arterial tones in all of her foot arteries. There was extensive ulceration on both legs. Her right leg (fig: 1a) had a large ulcer measuring 25cm x 14cm at its widest point. The ulcer was covered with 100% slough, which was thick and drying out in places. It was covered with a Hydrofiber dressing and Surgipad, which was saturated, causing maceration of the skin at the lower half of the ulcer. This resulted in wet footwear, bedding and carpets in the patient's home, causing her much distress.

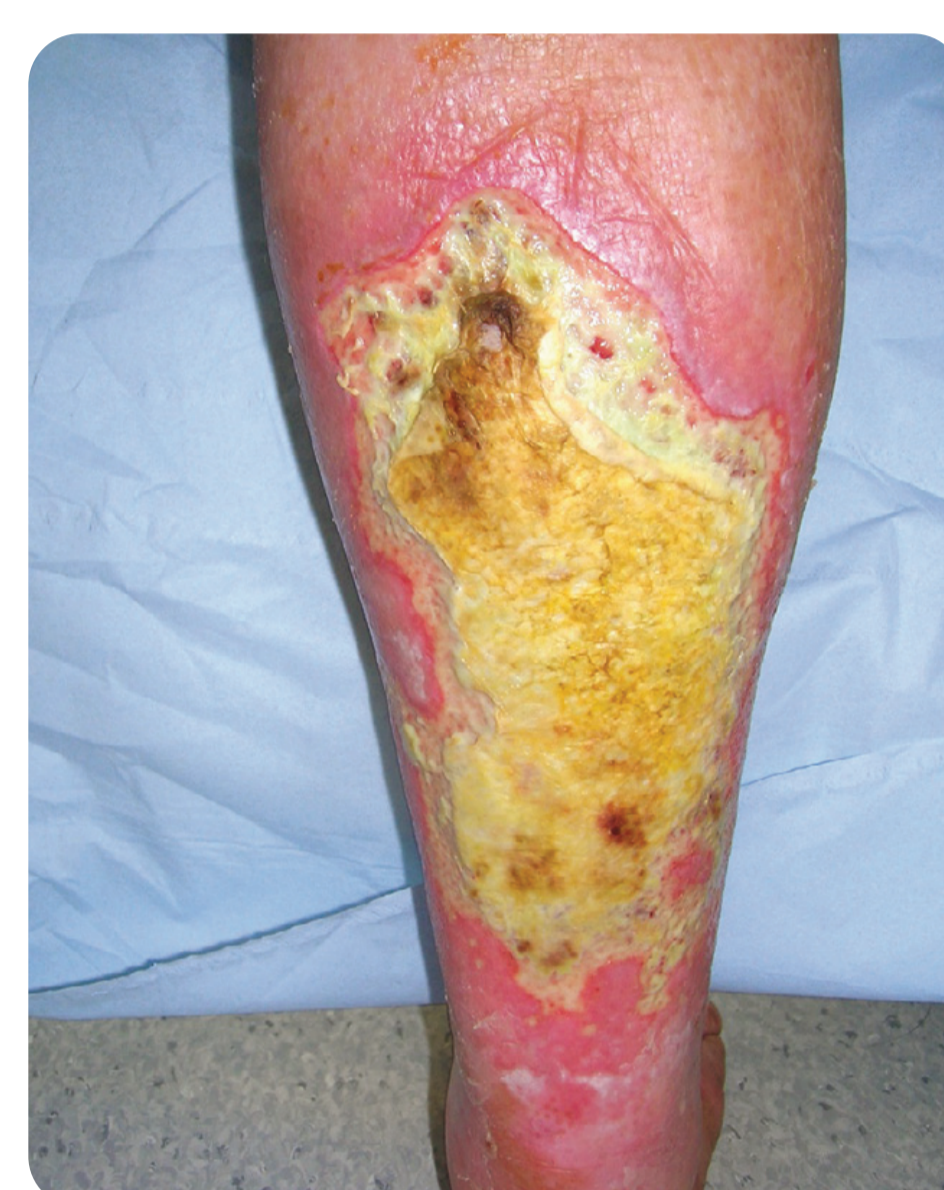

Fig: 1a

There were two areas of ulceration on the left leg (fig: 2a). One measured 8cm x 10cm, with a 4cm x 2cm central area of thick dehydrated blackened slough, which was surrounded by superficial slough. The smaller ulcer measured 1.5cm x 1.5cm, and was also covered with superficial slough. The ulcer was leaking copious amounts of serous fluid and the dressings (Aquacel and sterile pads filled with absorbent cotton in a fabric sleeve) were not effectively controlling the exudate, resulting in maceration of the peri-wound skin, especially to the lower half where exudate was dripping down the leg.

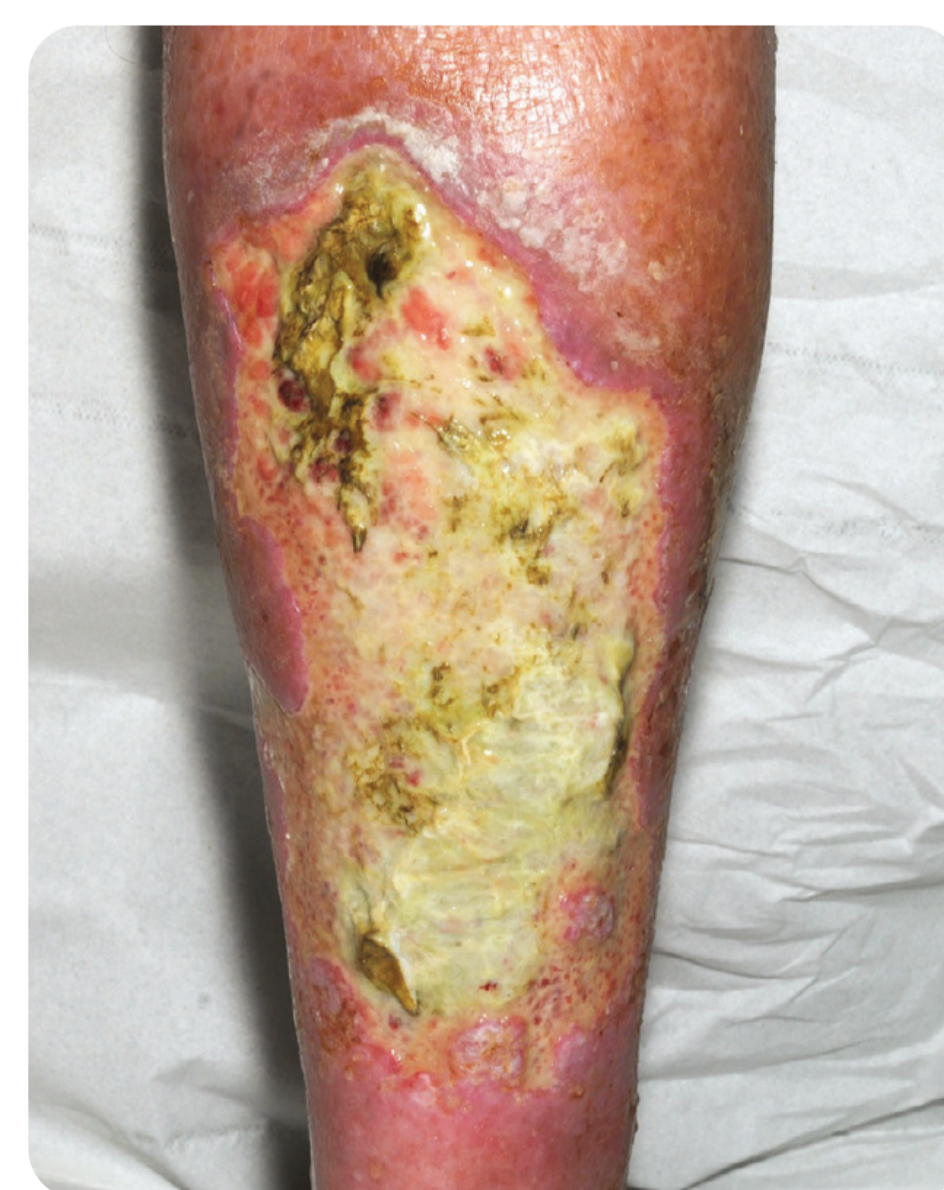

Fig: 2a

Diagnosis and treatment

The ulcers were thought to be a result of peripheral arterial disease with clinically occluded bilateral superficial femoral arteries. The patient was advised to undergo an angiogram and, if possible, an angioplasty, but was reluctant to do this until she had discussed it with her family.

The aim of the dressing usage was to control the exudate levels, preventing any further maceration, and to help debride the sloughy tissue and avoid infection. A honey-impregnated alginate dressing (Algivon®, Advancis Medical) was applied to the sloughy tissue to promote debridement and help absorb some of the exudate. This was covered with Advazorb® foam to manage the exudate, prevent further maceration and protect the damaged peri-wound skin, allowing it to heal. The dressings were secured with wool and crepe bandages and changed every 1–2 days, depending on extent of strikethrough.

Healing outcome

One week later, the patient was reviewed in clinic. On her right leg, the honey-impregnated alginate dressing was starting to lift the sloughy tissue (fig: 1b). More importantly, the Advazorb® foam was managing the exudate levels effectively. There were no further signs of maceration and the surrounding skin appeared healthy.

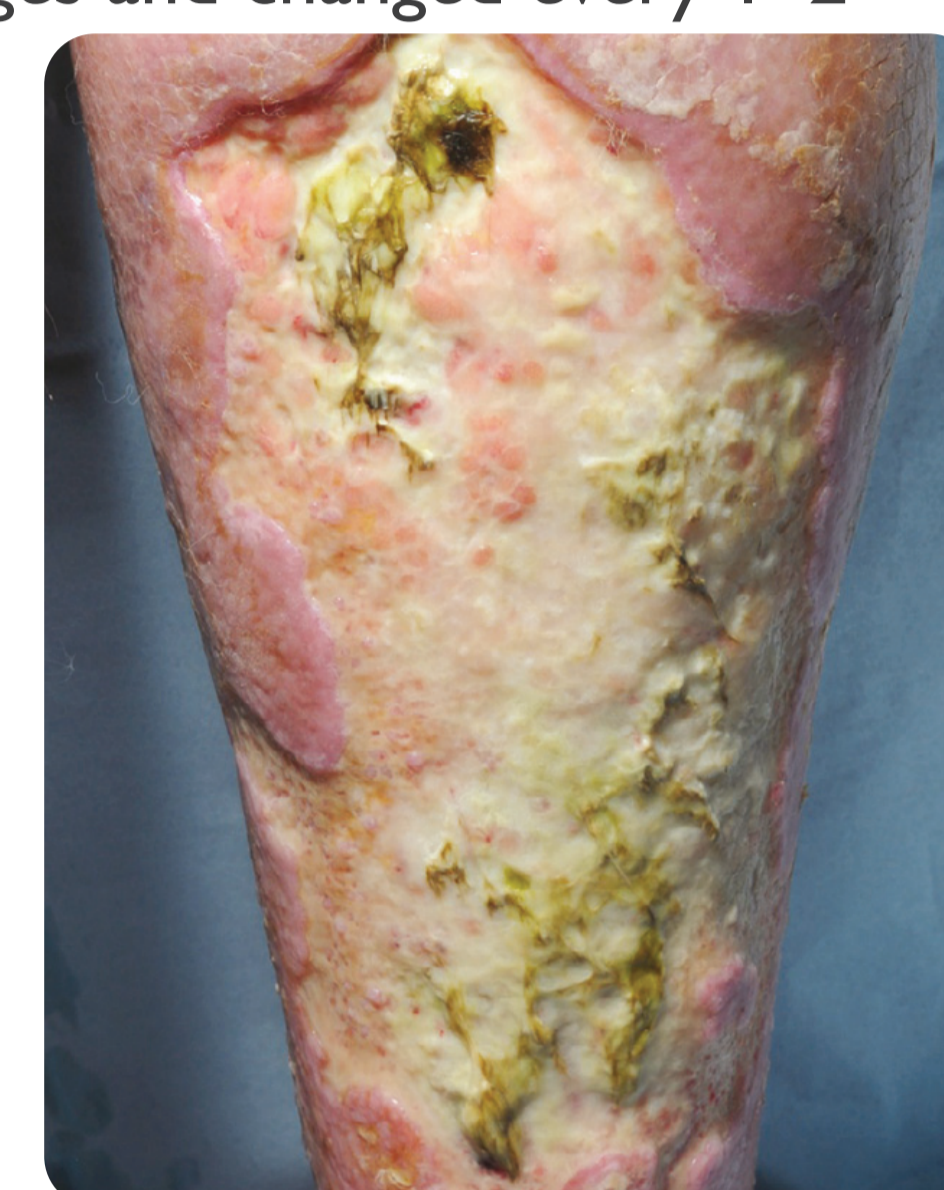


Fig: 1b

On her left leg (fig: 2b), the sloughy tissue was also starting to debride and the dry blackened slough was being rehydrated. The surrounding skin appeared healthy and the previously macerated areas had settled in only one week as the exudate was now being drawn into the Advazorb® dressings, which were successfully holding it away from the skin surface.

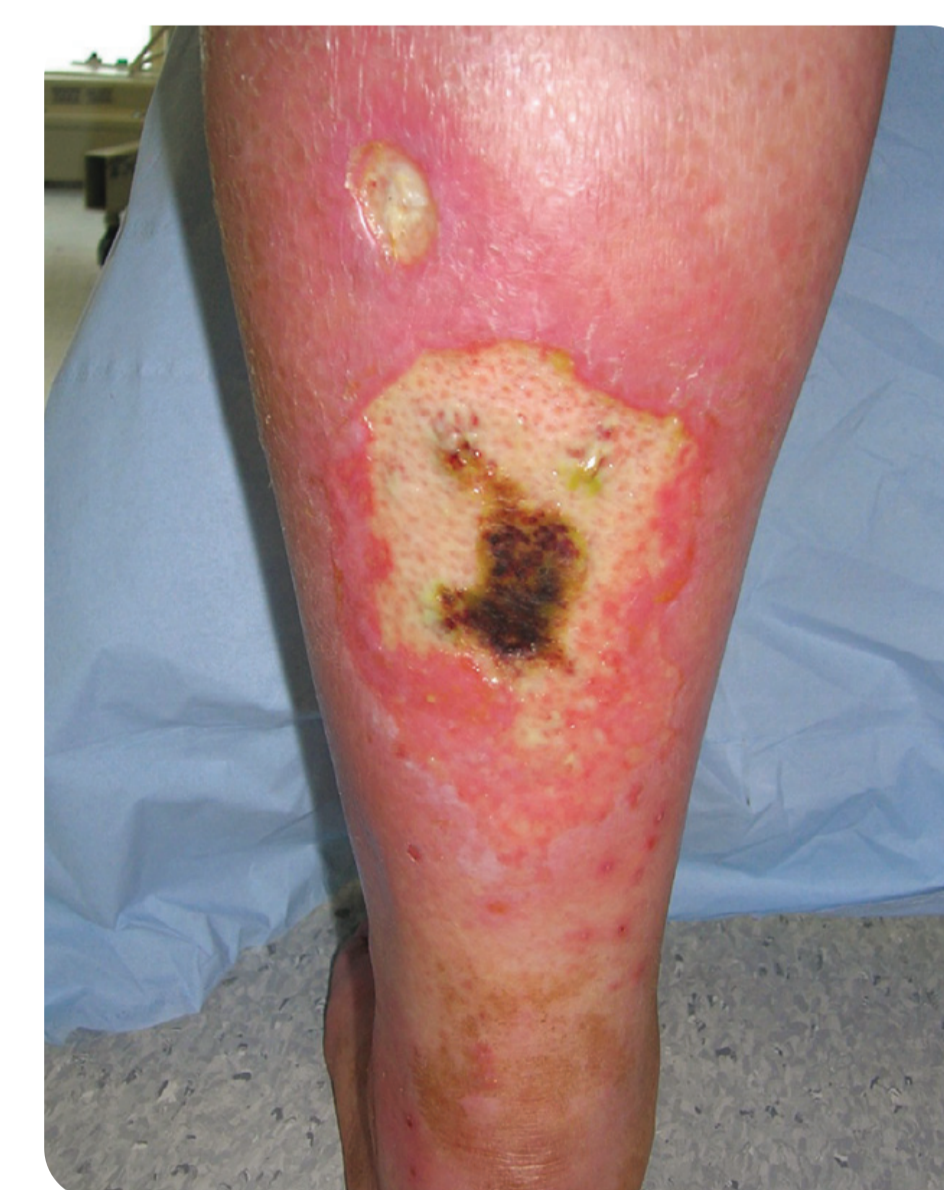

Fig: 2b

At this appointment, endovascular intervention was discussed again with the patient, who was still unsure whether she wanted to proceed with an angiogram. She reported that her legs had dramatically improved in only one week as the exudate levels were now being controlled and the burning pain she had been experiencing because

of the maceration had completely resolved. She was no longer troubled by wet bandages, which had impaired her quality of life. She wanted to continue with her current treatments.

When she was reviewed again the following week, the ulcer on her right leg (fig: 1c) continued to debride well; the thick sloughy tissue was mostly removed and the true depth of the ulcer was visible. The level of exudate was starting to reduce as the Advazorb® dressings continued to successfully manage it, preventing maceration. The ulcer on her left leg (fig: 2c) was now clear of dehydrated slough, with only a layer of superficial slough remaining. There was no further evidence of maceration and the surrounding skin appeared healthy. At this appointment, 3 weeks after presentation, the patient consented to an angiogram and possible angioplasty. It was hoped this would improve the blood supply to her lower legs, allowing the wounds to heal.

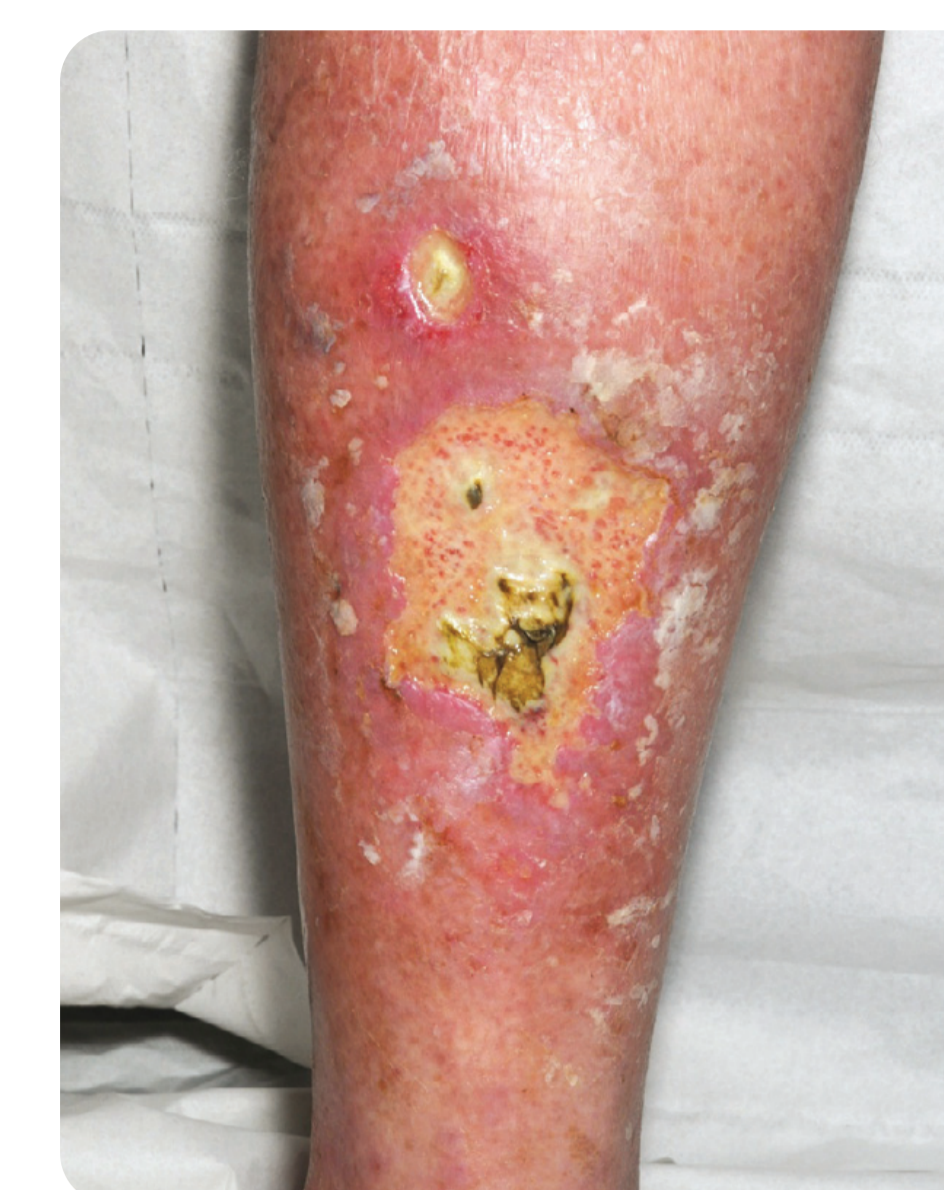

Fig: 1c

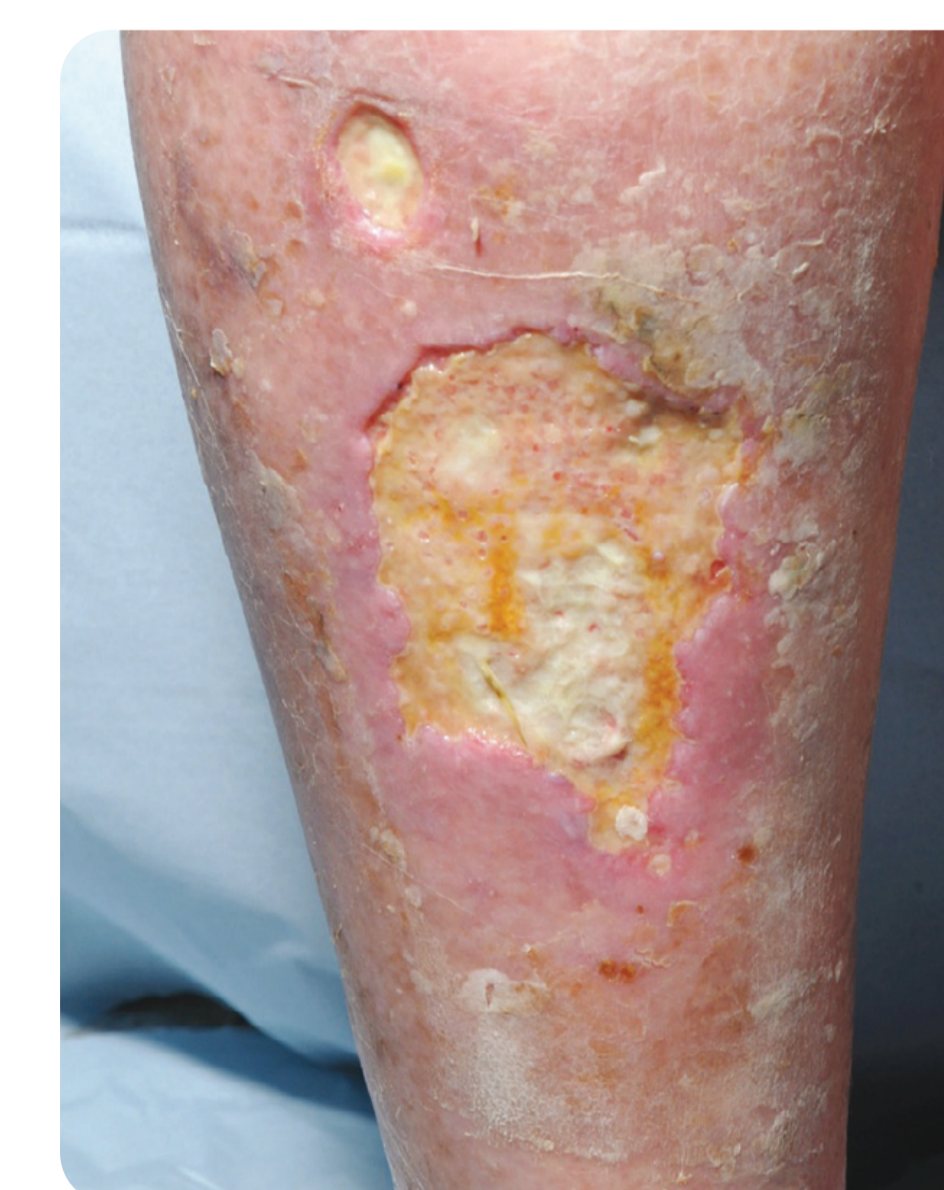

Fig: 2c

Benefits

The honey-impregnated alginate dressings rapidly debrided the thick sloughy tissue. The Advazorb® foam, on the other hand, was able to cope with high amounts of exudate and protect the previously macerated skin, allowing it to heal and preventing strikethrough. All of these improvements gave the patient the time she needed to carefully consider her treatment options in relative comfort.